

Buccolingual inclination of first molars in untreated adults: A CBCT study

Rola Alkhatib^a; Chun-Hsi Chung^b

ABSTRACT

Objective: To evaluate the buccolingual inclinations of maxillary and mandibular first molars in untreated adults.

Materials and Methods: Fifty-nine subjects (14 males and 45 females; mean age, 41.2 years) with no missing teeth, no crossbite, and minimal crowding were included. For each subject, a CBCT was taken. The long axis of each first molar was determined, and the inclination of each molar was measured using the long axis and the floor.

Results: One hundred seventeen out of 118 mandibular first molars measured had a lingual inclination, with a mean of $12.59^\circ \pm 5.47^\circ$. For the maxillary first molars, 107 out of 118 had a buccal inclination, with a mean of $4.85^\circ \pm 4.22^\circ$.

Conclusions: There is a curvature to the inclinations of first molars in untreated adults, where the maxillary molars have a slight buccal inclination and mandibular molars have a slight lingual inclination. (*Angle Orthod.* 0000;00:000–000.)

KEY WORDS: Untreated adults; Buccolingual inclination; CBCT

INTRODUCTION

It is generally accepted that the occlusal plane lies on a curve on which, when viewed from the front, the maxillary posterior occlusal surfaces comprise the convex part of the curve and the mandibular posterior occlusal surfaces are the concave part of the curve.¹ Early attempts to qualify the occlusal scheme include Bonwill,² who described a 4-inch equilateral triangle between the mandibular incisors and condyles. Monson³ used Bonwill's triangle as a basis for his description of the occlusal curvature as being a tangent to a sphere with a 4-inch radius. More recently, the occlusal curvature has been described as having a progressive increase in molar axial inclination from first

molar to third molar, a feature of evolution known as a *helicoid curve*.^{4,5} The general feature of the curvature, when viewed from the front, consists of a buccal inclination of the maxillary molars and a lingual inclination of the mandibular molars. Importantly, however, the specific amount of curvature had not been quantified.

Andrews⁶ described the six keys to normal occlusion. The third key relates to crown inclination, which he measured from buccal crown surfaces. His findings showed lingual crown inclination for the maxillary and mandibular molars; however, a large range in values was present. He reported a 27° range for the maxillary first molars and a 46° range for the mandibular first molars, yet this collection was considered to have "normal" occlusion.⁷

Today, the American Board of Orthodontics (ABO) evaluates clinically acceptable values for buccolingual inclinations of posterior teeth by comparing height differences between buccal and lingual cusps.⁸ The ABO states, "In order to establish proper occlusion in maximum intercuspation and avoid balancing interferences, there should not be a significant difference between the heights of the buccal and lingual cusps of the maxillary and mandibular molars and premolars."⁸

Age-related changes in the buccolingual inclinations of molars and their link to intermolar arch-width changes have been investigated previously.^{9,10} It was

^a Private Practice, Shelton, Conn.

^b Chauncey M.F. Egel Endowed Chair and Associate Professor, Department of Orthodontics, University of Pennsylvania School of Dental Medicine, Philadelphia, Pa.

Corresponding author: Dr Chun-Hsi Chung, Chauncey M.F. Egel Endowed Chair and Associate Professor, Robert Schattner Center, Department of Orthodontics, University of Pennsylvania School of Dental Medicine, 240 South 40th Street, Philadelphia, PA 19104
(e-mail: chunc@upenn.edu)

Accepted: February 2017. Submitted: November 2016.

Published Online: April 4 2017

© 0000 by The EH Angle Education and Research Foundation, Inc.

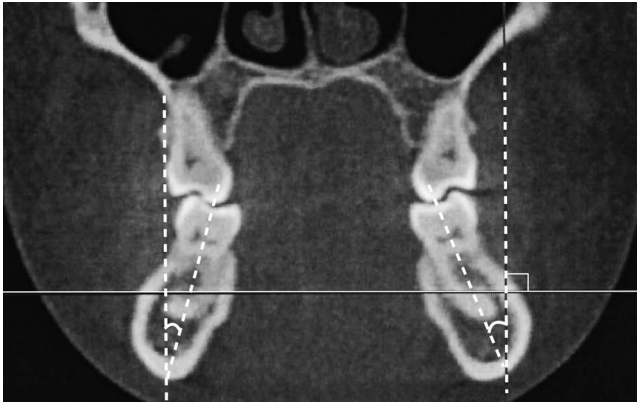


Figure 1. CBCT showing coronal section of mandibular first molars.

reported that both maxillary and mandibular molars upright with age while intermolar widths increase.^{9,10}

Based on the literature, information is lacking about the values for the buccolingual inclination of first molars in untreated adults. Barrera et al.¹¹ investigated the inclination of maxillary molars in adults using cone-beam CT (CBCT); of the 10 normocclusion adults, the average buccal inclination of the maxillary first molars was 4.05° per side. Kasai et al.¹² found that modern Japanese adult male skulls with relatively normal occlusion had mandibular first molars with an average lingual inclination of 13.3° per side. Thus far, no conclusions have been made regarding the quantification of the occlusal curvature in untreated adults.

The purpose of this study was to investigate, using CBCT, the degree of buccolingual inclination of maxillary and mandibular first molars in untreated adults.

MATERIALS AND METHODS

Institutional review board approval was obtained from the University of Pennsylvania before collecting any preexisting CBCT information. The images were previously taken in a private practice with an I-CAT machine (Imaging Sciences International, Hatfield, Pa) in 0.3-mm voxel size. A sample of 59 untreated adult subjects (15 male, 44 female), were selected (mean age: 41.2 years; median: 42, range: 18 to 65). Among them, 54 were white, 2 Asian, 1 Hispanic, and 2 black. The inclusion criteria were (1) no prior orthodontic treatment, (2) minimal dental wear, (3) less than 5 mm of crowding per arch, and (4) no missing teeth other than third molars. The exclusion criteria were (1) posterior crossbite, (2) crowns or significant restorations on any first molars, (3) presence of remaining primary dentition, (4) extensive dental restorations or wear, and (5) craniofacial deformities.

Using Dolphin Imaging (version 10.5, Dolphin Imaging and Management Solutions, Chatsworth,

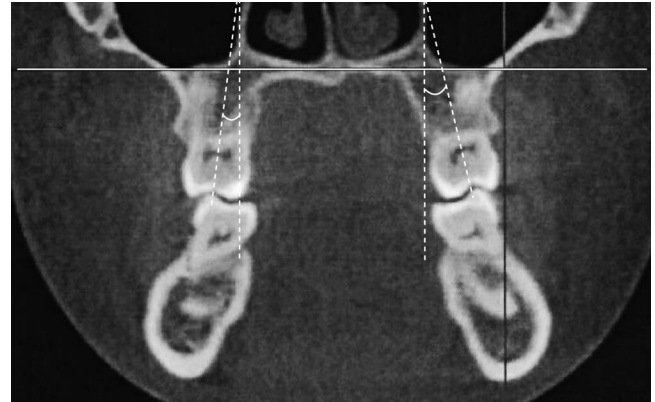


Figure 2. CBCT showing coronal section of maxillary first molars.

Calif), we standardized and oriented each image such that the Frankfort horizontal and a line connecting the inferior border of the orbital rims were parallel to the floor. The sagittal guideline of the tooth axis was defined (per Masumoto's guideline) as a line passing through the midpoint of the mesiodistal crown width and the midpoint between both middle points of each of the mesial and distal roots at one-third the distance from the apex.¹³ Once the sagittal orientation was determined, the coronal cross-section was obtained in a 0.5-mm slice, using a section that best fitted the right and left molar mesiodistal midpoints. The coronal section was used to measure the tooth axes. The long axis of the tooth was defined as a line connecting the midpoint of the buccal and lingual cusp tips and the midpoint of the buccolingual width at the cervical base of the anatomic crown (Figures 1 and 2). We then measured the angle from the long axis of each maxillary and mandibular first molar to a vertical reference line that was perpendicular to the horizontal reference line. If the crown was lingual to the roots, the inclination would be negative (–) and if it was buccal to the roots, the inclination would be positive (+).

Fourteen randomly selected subjects were measured again by the same examiner (R.A.) after 8 weeks to test for intraexaminer reproducibility. A paired *t*-test was run for tooth inclination measurements to determine whether there were significant differences from the original measurements. The significance was predetermined at $P < .05$. The mean, standard deviation, and range were calculated for each inclination.

RESULTS

The intraexaminer reliability test showed no significant differences between tooth inclination measurements. Pearson correlation coefficients varied between 0.95 and 0.99 for the measurements, indicating high reproducibility.

Table 1. Inclinations of Mandibular First Molars

Tooth	<i>n</i>	Mean (°)	SD ^a	Minimum Value (°)	Maximum Value (°)
Mandibular right first molar	59	-12.81	5.68	-25.0	+3.0
Mandibular left first molar	59	-12.39	5.29	-27.0	-2.5
Average, mandibular first molars	118	-12.60	9.2	-27.0	+3.0

^a SD indicates standard deviation.

A (-) value indicates lingual inclination; (+), buccal inclination.

Table 1 shows the mandibular first molar inclinations. The mandibular right first molar displayed an average of $-12.81^\circ \pm 5.68^\circ$ and the mandibular left first molar displayed $-12.39^\circ \pm 5.29^\circ$ of lingual inclination. The average was $-12.60^\circ \pm 5.29^\circ$. There was no significant difference between the right and left values ($P > .05$). Only one mandibular right first molar had a buccal inclination of 3° .

Table 2 shows the values for the maxillary first molar inclinations. The maxillary right first molar displayed an average of $+5.62^\circ \pm 4.12^\circ$ and the maxillary left first molar displayed $+4.08^\circ \pm 4.23^\circ$ of buccal inclination. The average was $+4.85^\circ \pm 4.22^\circ$. There was no significant difference between the right and left mean values. One hundred seven out of 118 had a buccal inclination. Of the 11 that were lingually inclined, 2 had 5.0° of inclination, 2 had 3° , 1 had 2° , and 6 had 1° . In addition, six had 0° inclination, meaning they were upright.

DISCUSSION

Untreated adult males and females were examined, and the findings were combined due to a lack of significant difference according to the paired *t* test ($P > .05$). Previous studies also combined male and female data.^{10,11,14-16}

One of the advantages of using CBCT is the ability to visualize the whole tooth, thus removing some of the uncertainty in long-axis inclination that can result from using casts with uneven cusp wear or tooth morphology.^{11,14,16,17} In this study, the whole anatomic crown was used to determine the long axis of the first molars. This would eliminate any uncertainty due to variation in root morphology or divergence. Determining the tooth axis for the maxillary molars poses specific challenges because of frequent divergence between the maxillary molar roots. Mitra¹⁷ measured maxillary molar inclinations using CT; however, only the buccal roots were measured. Barrera et al.¹¹ used a line connecting the central groove to the furcation for the molar axis, which

is similar to the method used in this study. Shewin-nakitkul et al.¹⁴ measured the long axis of the mandibular first molars using a line from the central groove to the middle of the apices. Using the whole root without factoring in dilacerations may skew results. Kasai and Kawamura¹² defined the long axis as passing through the midpoint at one-half the crown width and the midpoint at one-third the distance from the apex. This accounts for the potential of root dilacerations, but not anomalous root morphology or whole root divergence. Using the whole crown with the aid of three-dimensional imaging may provide the most accurate assessment of long axis determination for both maxillary and mandibular molars.

While there are advantages in visualizing the long axis of teeth using three-dimensional technology, it would not be ethical to expose normal patients requiring no treatment to radiation. To obtain an adequate sample size, we adjusted the inclusion and exclusion criteria as indicated, maintaining a reasonably tight standard and excluding patients with missing teeth, crossbite, or more than 5 mm of crowding. If all subjects included had been ideal and possessed normal occlusion, we might have expect some small differences in the inclination values obtained.

The results of the current study are consistent with previous reports of the occlusal scheme demonstrating the presence of an occlusal curvature in untreated dentitions.²⁻⁷ The findings suggest that mandibular first molars in untreated adults have a mean lingual inclination of 12.6° ; however, there is limited literature reporting values for this inclination. Ross et al. measured untreated ideal subjects and demonstrated a mean mandibular molar lingual inclination of $7.1^\circ \pm 4.6^\circ$, but that study combined subjects between the ages of 9.5 and 41.5 years and was performed on casts.¹⁵ Tong et al.¹⁶ used a custom root vector-analysis software to measure whole-tooth inclination in near-normal patients with CBCT and found a mean of -8.51° for the mandibular first molars.¹⁶ Yet, their

Table 2. Inclinations of Maxillary First Molars

Tooth	<i>n</i>	Mean (°)	SD	Minimum Value (°)	Maximum Value (°)
Maxillary right first molar	59	+5.62	4.12	-5.0	+15.5
Maxillary left first molar	59	+4.08	4.23	-5.0	+14.0
Average, maxillary first molars	118	+4.85	4.22	-5.0	+15.5

sample did include an age range from 12 to 36 years. Shewinvanakitkul et al.¹⁴ found a lingual inclination of $15.4^\circ \pm 4.7^\circ$ in mandibular first molars in untreated Class I patients; however, their subjects had a mean age of only 13.2 years. Based on previous studies, changes in axial inclination can be expected consistent with growth, so studies including growing patients may not yield reliable values.^{9,10} Marshall et al.¹⁰ also used casts to measure cusp inclinations, reporting a mandibular first molar lingual inclination of $2.08^\circ \pm 4.80^\circ$ for the mesiolingual cusp of the left first molar at age 26.4 and $4.53^\circ \pm 5.86^\circ$ for the distolingual cusp of the right first molar at age 26.4. Measurement of the individual cusps, while demonstrating the tendency toward lingual inclination of the mandibular first molar occlusal surfaces, does not yield any inclination values representative of the long axis of that tooth.

In the current sample, the buccal inclination of maxillary first molars was observed in 90.7% of the teeth measured. For the 11 out of 118 that did not display buccal inclination, 5° of lingual inclination was the greatest deviation, seen in two of the measured first molars in two different subjects. Interestingly, six of the first molars measured were completely upright. Mean buccal inclination was 4.85° per side. The Barrera et al.¹¹ three-dimensional evaluation of the curve of Wilson reported 4.05° of crown torque for each side, but their normocclusion sample size was only 10 subjects. Tong et al.¹⁶ reported a mean 4.73° of buccal inclination for the maxillary first molars with their volumetric measurements. In their ideal occlusion group, Ross et al.¹⁵ reported a mean buccal inclination of $8.0^\circ \pm 4.0^\circ$ in the maxillary first molars in a group of subjects aged 9.5 to 41.5 years and using casts.

An interesting observation was made during analysis of the coronal cuts in that the basal bone inclination frequently aligned with the lingual inclination of the mandibular molars. Basal bone inclination was not measured specifically, although the general trend was evident. The Kohakura et al.¹⁸ CT scans of male Asiatic Indians showed a similar relationship between the tooth axis and bone axis, in which the mandibular first molar averaged $10.18^\circ \pm 4.8^\circ$ of lingual inclination and the bone inclination averaged $8.35^\circ \pm 5.2^\circ$. It would be interesting to further pursue the relationship between molar inclination and bone inclination in untreated adults.

With the maxillary first molars at a mean buccal inclination of 4.85° and mandibular first molars at a mean lingual inclination of 12.6° , the maxillary first molars tended to be more upright than the mandibular first molars. When we compared Andrews¹⁷ inclinations for the maxillary and mandibular first molars, a similar trend was observed, with the maxillary first molars being more upright at a mean inclination of 11.53° ,

compared with the mandibular first molars at a mean inclination of -30.67° .

According to Dawson,¹⁹ there are two reasons for the existence of the curve of Wilson. The first is for optimal resistance to loading, whereby the buccolingual inclination of the posterior teeth parallels the inward pull and orientation of the internal pterygoid muscle contraction to produce the greatest resistance to masticatory forces. Secondly, inward inclination of the occlusal table allows open access to food as it is being chewed, facilitating the masticatory process. Okeson¹ explained that the occlusal curvature exists to have the most effective use of cuspal contacts, while avoiding nonfunctional contacts known as *balancing interferences*. Nanda²⁰ stated that a small curve of Wilson between the buccal segments allows for proper occlusal function, but that "an accentuated curve will result in balancing interferences, especially in the second molar area." It is important to find out what an appropriate amount of buccolingual tooth inclination is for adequate function, and to quantify it so that we can have treatment goals that are well-supported by evidence. Given the orientation of anatomic structures described by Dawson,¹⁹ it would be expected that the bone inclination would also be oriented this way for optimal masticatory loading.

A potential link between buccolingual inclination of molars and vertical facial type has been studied, but the results are scattered and inconsistent.^{13,15,17,21,22} Janson et al. found that there was no statistical variation between low- and high-angle subjects in mandibular posterior tooth inclination, but maxillary molars had greater buccal inclinations in high-angle subjects.²¹ Conversely, Tsunori et al. found that short facial types had more lingual molar inclination in the mandible.²²

Orthodontic philosophies have varied in their rationale of an occlusal curvature and molar torque. Andrews²³ explained, in his six-element philosophy, that "each crown must be inclined so that the occlusal surface can interface and function optimally with the teeth in the opposing arch." McNamara²⁴ suggested that one of the goals of orthodontic treatment should be to flatten the occlusal plane and level the curve of Wilson. Conversely, Dawson¹⁹ stated that when the curve of Wilson is made too flat, ease of masticatory function may be impaired. The ABO suggests that either maxillary buccal cusps or mandibular lingual cusps be no more than 1 mm off the surface of a straight edge.⁸ It would therefore be logical to consider maintaining some degree of a curve of Wilson after orthodontic treatment, to be consistent with the physiologic needs of masticatory function and to encourage stability of treatment by remaining consistent with natural findings. The current findings support

the natural presence of a mild curve of Wilson in untreated adults. Further studies are warranted to investigate normal values for buccolingual inclination of the entire posterior dentition.

Andrews⁷ reported a large range of values of buccolingual inclination for maxillary and mandibular first molars in a sample of normal untreated patients. Our study showed similar results. With such a wide range present in untreated subjects, there may be other factors influencing tooth inclination. There are currently various prescriptions available to clinicians to treat patients, yet the idea of a one-prescription-fits-all approach to treatment is often employed because of its simplicity. However, care must be exercised regarding how much torque to actually express to achieve successful treatment outcomes. Dellinger²⁵ wrote that “if full-sized unbent arch wires are placed in the mouth and are allowed to totally work out, that the results could be erratic, inconsistent, and clinically unacceptable.” Ross¹⁵ also argued that no straightwire appliance fully expressed can be expected to be correct for all patients. It is possible that just like treatment goals, choice of prescription and degree to which torque is expressed, may need to be tailored to individual patients.

CONCLUSIONS

- Maxillary first molars in untreated adults had an average buccal inclination of $4.85^\circ \pm 4.22^\circ$.
- Mandibular first molars in untreated adults had an average lingual inclination of $12.60^\circ \pm 5.29^\circ$.
- Maxillary molars are naturally more upright than mandibular molars.

ACKNOWLEDGMENTS

The authors thank Drs. Normand Boucher, Ashish Gu, and Amirtha Hariharan for their help in this project.

REFERENCES

1. Okeson JP. *Management of Temporomandibular Disorders and Occlusion*. 7th ed. St. Louis: Elsevier; 2012.
2. Bonwill WGA. Geometrical and mechanical laws of articulation. *Trans Odontol Soc Pa*. 1885;119–133.
3. Monson GS. Applied mechanics to the theory of mandibular movements. *Dent Cosmos*. 1932;74:1039–1053.
4. Ackerman F. The helicoid principle in human dental occlusion. *Int Dent J* 1963;13:532.
5. Smith BH. Development and evolution of the helicoidal plane of dental occlusion. *Am J Phys Anthropol*. 1986;69:21–35.
6. Andrews LF. The six keys to normal occlusion. *Am J Orthod*. 1972;62:296–309.
7. Andrews LF. *Straight Wire: The Concept and the Appliance*. San Diego: L.A. Wells; 1989.
8. Casco JS, Vaden JL, Kokich VG, et al. Objective grading system for dental casts and panoramic radiographs. American Board of Orthodontics. *Am J Orthod Dentofacial Orthop*. 1998;114:589–599.
9. Hesby R, Marshall S, Dawson D, et al. Transverse skeletal and dentoalveolar changes during growth. *Am J Orthod Dentofacial Orthop*. 2006;130:721–731.
10. Marshall S, Dawson D, Southard KA, Lee AN, Casco JS, Southard TE. Transverse molar movements during growth. *Am J Orthod Dentofacial Orthop*. 2003;124:615–624.
11. Barrera JM, Llamas JM, Espinar E, Sáenz Ramírez C, Paredes V, Pérez-Varela JC. Wilson maxillary curve analyzed by CBCT. A study on normocclusion and malocclusion individuals. *Med Oral Patol Oral Cir Bucal*. 2013;18:547–552.
12. Kasai K, Kawamura A. Correlation between buccolingual inclination and wear of mandibular teeth in ancient and modern Japanese. *Arch Oral Biol*. 2001;46:269–273.
13. Masumoto T, Hayashi I, Kawamura A, Tanaka K, Kasai K. Relationships among facial type, buccolingual molar inclination, and cortical bone thickness of the mandible. *Eur J Orthod*. 2001;23:15–23.
14. Shewinvanakitkul W, Hans MG, Narendran S, Martin Palomo J. Measuring buccolingual inclination of mandibular canines and first molars using CBCT. *Orthod Craniofac Res*. 2011;14:168–174.
15. Ross VA, Isaacson RJ, Germane N, Rubenstein LK. Influence of vertical growth pattern on faciolingual inclinations and treatment mechanics. *Am J Orthod Dentofacial Orthop*. 1990;98:422–429.
16. Tong H, Kwon D, Shi J, Sakai N, Enciso R, Sameshima GT. Mesiodistal angulation and faciolingual inclination of each whole tooth in 3-dimensional space in patients with near normal occlusion. *Am J Orthod Dentofacial Orthop*. 2012;141:604–617.
17. Mitra S, Ravi MS. Evaluation of buccolingual inclination of posterior teeth in different facial patterns using computed tomography. *Ind J Dent Res*. 2011;22:376–380.
18. Kohakura S, Kasia K, Ohno I, Kanazawa E. Relationship between maxillofacial morphology and morphological characteristics of vertical sections of the mandible obtained by CT scanning. *J Nihon Univ Sch Dent*. 1997;39:71–77.
19. Dawson PE. *Functional Occlusion: From TMJ to Smile Design*. St. Louis: Mosby; 2007.
20. Nanda R. *Biomechanics and Esthetic Strategies in Clinical Orthodontics*. St. Louis: Elsevier Saunders; 2005.
21. Janson G, Bombonatti R, Cruz KS, Hassunuma CY, Del Santo M Jr. Buccolingual inclinations of posterior teeth in subjects with different facial patterns. *Am J Orthod Dentofacial Orthop*. 2004;125:316–322.
22. Tsunori M, Mashita M, Kasai K. Relationship between facial types and tooth and bone characteristics of the mandible obtained by CT scanning. *Angle Orthod*. 1998;68: 557–562.
23. Andrews LF, Andrews WA. The six elements of orofacial harmony. *Andrews J Orthod Orofacial Harmony*. 2000;1:13–22.
24. McNamara JA, Brudon WL, Kokich VG. *Orthodontics and Dentofacial Orthopedics*. Ann Arbor, Mich: Needham; 2001.
25. Dellinger EL. A scientific assessment of the straight-wire appliance. *Am J Orthod*. 1978;73:290–299.